

i-CAT Cone Beam Volumetric Tomography Scan

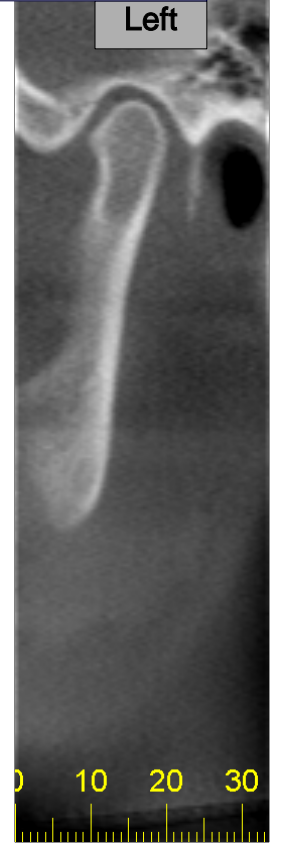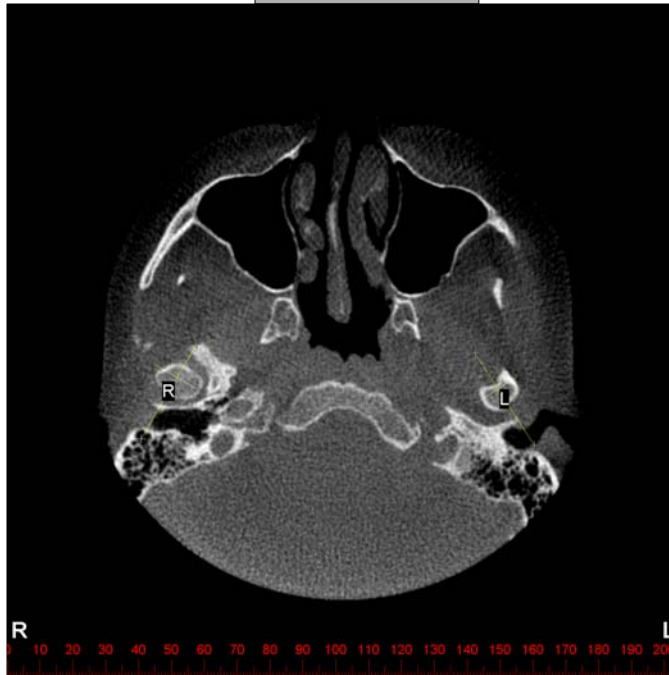
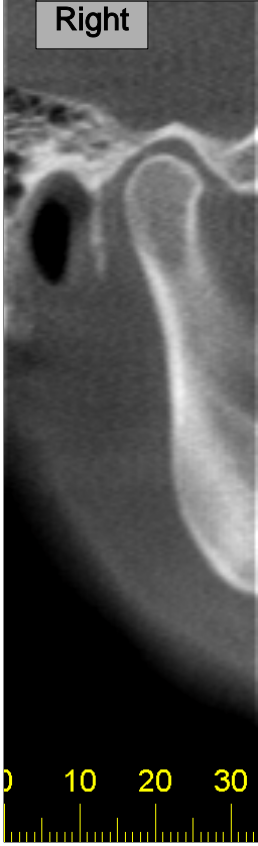Imaging Sciences International Inc.
1910 North Penn Road
Hatfield, PA 19440
Tel: (215) 997-5666

Patient: Sample Frontal TMJ Report
DOB: 01/01/1970
Referred by:
Study Date: 02/22/2005

Right

Left

SMV View



All Frontal & Lateral images are actual size (1:1)

Right Frontal

Left Frontal

